



FIG 1: CT SCAN. Right perihilar mass with adjacent subcarinal adenopathy. Other CT sections showed suspicious paratracheal lymph nodes.

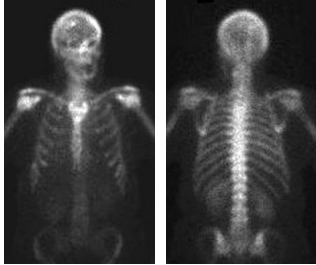


FIG 2: BONE SCAN. Anterior and posterior bone scan images suggest a solitary bone metastasis in the calvarium.

Lung Cancer Staging. PET Shows Extensive Stage IV Disease.

A 59-year old woman presented with a right lower lobe lung carcinoma and suspicious mediastinal adenopathy. A staging PET scan was requested.

DISCUSSION: PET scan not only confirmed mediastinal disease, it also showed multiple areas of abnormal uptake in the liver and skeleton compatible with active tumor that was not demonstrated on CT or bone scan. PET was the only imaging modality that showed the true extent of the patient's disease.

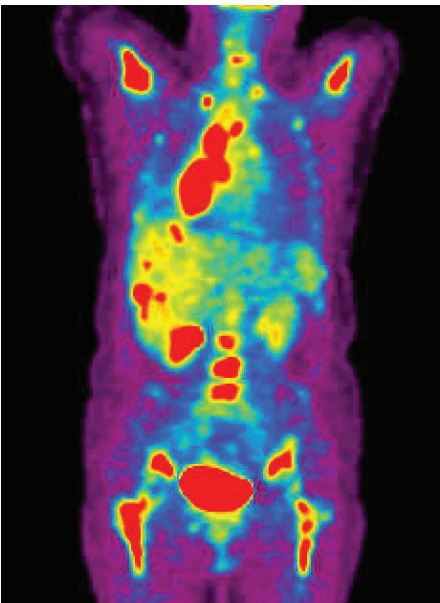


FIG 3: PET SCAN. Coronal PET image confirms active tumor in the right lower lobe and demonstrates extensive bilateral mediastinal nodal uptake compatible with tumor. PET also shows multiple hypermetabolic foci in the liver highly suspicious for metastases, despite the normal appearing liver on CT.

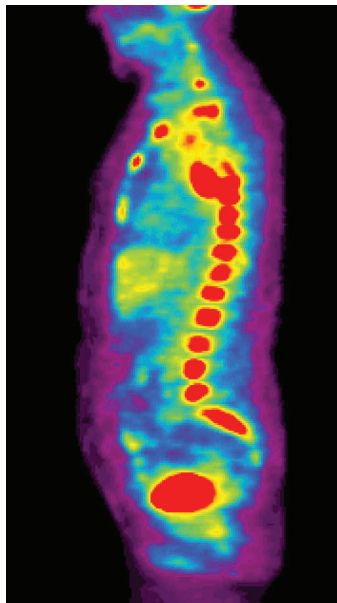


FIG 4: PET SCAN. Sagittal PET image shows extensive abnormality involving nearly the entire spine compatible with bone metastases. Lesions are also present diffusely in the sternum, pelvis, long bones and ribs.

My patient has already been diagnosed with non-small cell lung cancer. Is PET still helpful?

Yes. PET more accurately stages lung cancer than CT. PET improves upon CT staging because it can confirm malignancy in suspicious but not clearly abnormal CT findings such as shotty mediastinal lymph nodes or small adrenal masses. PET has been shown to have a higher sensitivity, specificity and accuracy than CT in mediastinal staging¹:

	Sensitivity	Specificity	Accuracy
CT	75%	66%	69%
PET	91%	86%	87%

My patient has newly diagnosed non-small cell lung cancer with CT findings suspicious for metastatic disease. Is PET still helpful?

Yes. Since PET is more sensitive than CT, it often shows more disease than is evident on CT. For example, CT may show a patient with a malignant lung mass and clearly enlarged abnormal mediastinal nodes, while the PET may confirm these findings and also show unsuspected adrenal or supraclavicular nodal metastases, which would indicate evidence for stage IV disease. In a study of 102 patients with histopathological analysis, PET downstaged disease in 20% of patients and upstaged disease in 41% of patients compared with CT¹.

My patient has already received therapy for lung carcinoma. Does PET have a role in treatment monitoring and restaging?

Yes. The benefits of PET already described above also apply to patients with known disease. For example, PET can help distinguish benign pleural scarring due to radiotherapy from pleural metastases. Additionally, sequential PET scans can show how a patient is responding to therapy.

My patient is elderly or debilitated. Is PET difficult for the patient? Is it safe?

In general, PET is not a difficult test and it is very well tolerated by patients. The PET scanner is similar to a CT scanner. Total imaging time is approximately 40 minutes. The radiation exposure associated with PET is similar to CT and there are no side effects from the tracer.

Pieteman et al. N Engl J Med 2000; 343(4):254-261.

FOR MORE INFORMATION REGARDING PET AND FOR COPIES OF THE CLINICAL ARTICLES SUPPORTING ITS USE, PLEASE CALL 732-246-0064.



U N I V E R S I T Y R A D I O L O G Y P E T C E N T E R



75 VERONICA AVE SOMERSET NJ 08873

